Technical Note

Rotator Interval Plication: The "Seamster" Technique

Jace R. Smith, M.D., and Larry D. Field, M.D.

Abstract: The indications and best technique for plication of the rotator interval capsule, performed as a supplemental procedure at the time of arthroscopic shoulder stabilization, remain a controversial topic. There are currently no well-accepted surgical indication guidelines that have been established. Several biomechanical studies, however, have demonstrated the important contribution of the rotator interval capsule to stability of the glenohumeral joint, and the utilization of rotator interval plication in patients with glenohumeral instability has been supported in several publications. The indications for and surgical steps to accomplish the arthroscopic "seamster" technique for rotator interval plication, used by the authors for >20 years, is described.

Introduction

The rotator interval is a triangular space that is located in the anterosuperior aspect of the glenohumeral joint. The superior border is composed of the anterior margin of the supraspinatus, the inferior border is marked by the superior margin of the subscapularis tendon, and the medial base of the triangle is bounded by the anterior glenoid rim (Fig 1). The rotator interval includes portions of the supraspinatus, subscapularis, coracohumeral ligament (CHL), superior glenohumeral ligament (SGHL), middle glenohumeral ligament (MGHL) and glenohumeral joint capsule.[1,2] It has been identified as a structure that contributes to glenohumeral joint stability.[3] Likewise, multiple biomechanical studies have demonstrated the importance of the CHL and SGHL as restraints to humeral translation in the inferior and posterior directions.[4-6]

Although the specific instability patterns and arthroscopic findings suitable to justify rotator interval plication remain debatable and controversial, there is support by some shoulder surgeons for the supplemental use of rotator interval plication.[7-9] Based on work performed by Harryman et al.,[6] rotator interval plication may be beneficial for cases of posterior instability. Harryman et al.[6] also found that rotator interval plication aids in the reduction of capsular volume and reestablishes capsuloligamentous tension in patients with multidirectional instability. When rotator interval plication is carried out, it should be delayed until the final step of the arthroscopic stabilization procedure, because plication of the rotator interval precludes further access to the to the glenohumeral joint though the rotator interval capsule.

Indications

The indications for rotator interval plication remain controversial. However, rotator interval plication may be considered in patients with the symptomatic inferior laxity that does not resolve in external rotation with the arm at the side or in patients with multidirectional instability (MDI).[10] Patients with MDI often have hyperlaxity and a prominent sulcus sign on physical examination. Other potential indications for rotator interval plication include patients with thin or poor capsular tissue and patients undergoing arthroscopic stabilization in a revision surgical setting.[11,12]

Plication of the rotator interval capsule is commonly carried out in clinical situations regardless of whether the rotator interval is considered abnormally patulous. Plication of a normal appearing interval capsule can effectively reduce translations and contribute to overall glenohumeral joint stability.[6] The rotator interval capsule is also sometimes recognized as abnormally patulous or damaged when viewed arthroscopically.

From the Mississippi Sports Medicine and Orthopaedic Center, Jackson, Mississippi, U.S.A.

The authors report that they have no conflicts of interest in the authorship and publication of this article and that no funding or financial remuneration was received. Full ICMJE author disclosure forms are available for this article online, as supplementary material.

Received February 13, 2019; accepted May 20, 2019.

Address correspondence to Larry D. Field, M.D., Upper Extremity Service, Sports Medicine and Arthroscopy Fellowship, Mississippi Sports Medicine and Orthopaedic Center, 1325 East Fortification Street, Jackson, MS 39202, U.S.A. E-mail: lfield@msmoc.com

2212-6287/19186

https://doi.org/10.1016/j.eats.2019.05.025

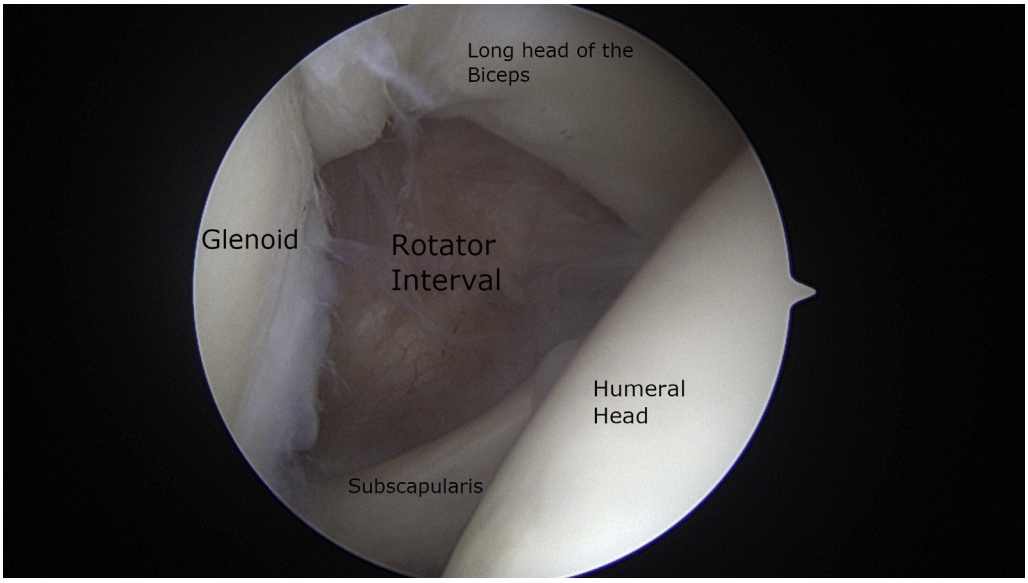

Fig 1. Arthroscopic view of the rotator interval with identification of the borders including the subscapularis and anterior rim of the glenoid while viewing from the posterior portal using a 30° arthroscope in a right shoulder in the lateral decubitus position.

When the rotator interval capsule is visualized from the posterior portal, an abnormally patulous bulging of the capsule (Fig 2), a drooping capsule (Fig 3), or a significantly widened interval (Fig 4) can all be identified. A significantly widened interval capsule is seen to extend superior to the biceps tendon when viewed arthroscopically from the posterior portal site.[13]

Operative Technique

The technique, described here, is referred to by the authors as the "seamster" technique because of the nature in which the suture is advanced across the rotator interval capsule using a suture retriever; this suture placement is very similar to how thread is advanced through fabric by a sewing machine needle.[13] The "seamster" technique not only effectively and reliably plicates the intra-articular superior glenohumeral ligament to the intra-articular middle glenohumeral ligament but, importantly, also allows for incorporation of the extra-articular coracohumeral ligament (Video 1). After regional or general anesthesia is induced, the operative shoulder is examined under anesthesia and compared with the contralateral shoulder to assess for stability and motion. The authors then position the patient in the lateral decubitus position (Fig 5) with the arm suspended in a balanced position with approximately 10 lb of weight. The "seamster" technique for rotator interval plication, however, can

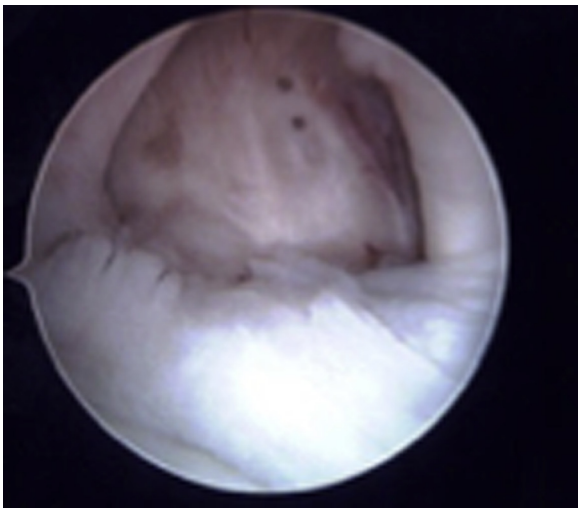

Fig 2. Arthroscopic view of an abnormally patulous bulging of the capsule while viewing from the posterior portal using a 30° arthroscope in a right shoulder in the lateral decubitus position.

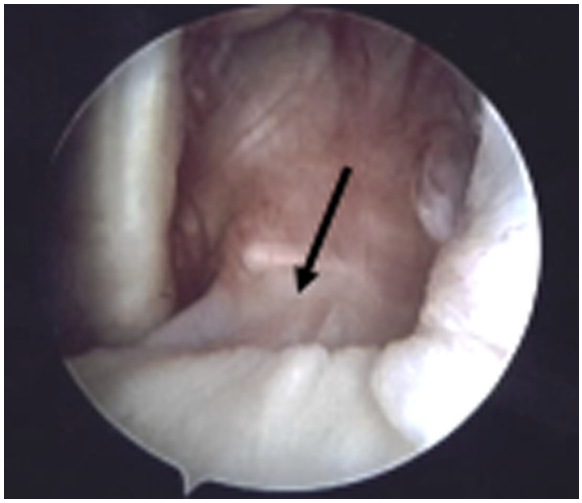

Fig 3. Arthroscopic view of a drooping capsule while viewing from the posterior portal using a 30° arthroscope in a left shoulder in the lateral decubitus position.

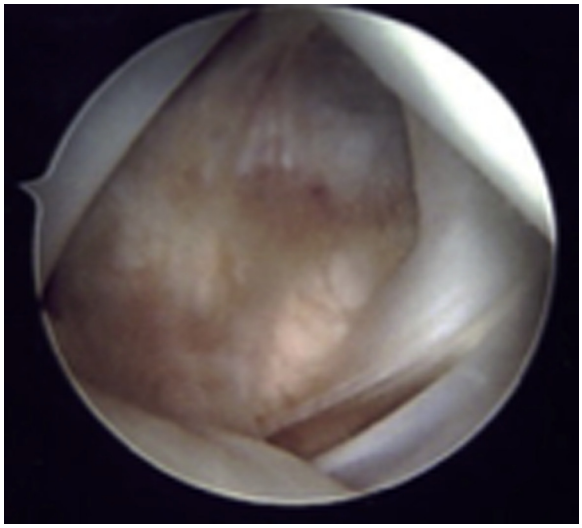

Fig 4. Arthroscopic view of a significantly widened rotator interval while viewing from the posterior portal using a 30° arthroscope in a right shoulder in the lateral decubitus position.

also be performed without compromise in the beach chair position. A marking pen is used to identify shoulder landmarks and proposed portal sites (Fig 6). A standard posterior arthroscopy portal is then established, and a 30° arthroscope is inserted. The rotator interval is identified anteriorly. Next, an 18-gauge spinal needle is used to establish the location for an anterior inferior portal from outside-in with the needle inserted into the joint just superior to subscapularis tendon. An 8-mm threaded cannula is inserted, and a thorough diagnostic arthroscopy is performed. The arthroscopic stabilization procedure of choice is then carried out. Rotator interval plication is always performed as the final step following completion of the Bankart repair, capsular plication, Remplissage, or other stabilization procedure.

Fig 5. After general anesthesia is induced, patient is positioned in a standard lateral decubitus position for a left shoulder procedure.

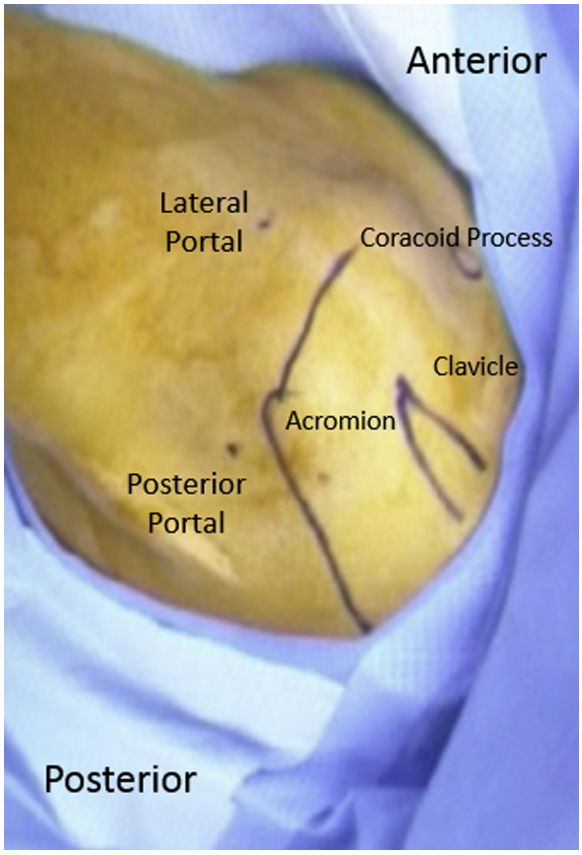

Fig 6. Marking pen is used to identify acromion, clavicle, and coracoid processes along with posterior and lateral portals on the left shoulder in the lateral decubitus position with the arm in balanced suspension.

The "seamster" technique for rotator interval plication is accomplished while viewing the rotator interval capsule using a 30° arthroscope via the standard posterior portal site. An anterosuperior portal, if not already established to perform the primary stabilization procedure such as Bankart or capsulorrhaphy, is created at the anterior and lateral margin of the acromion with the spinal needle entering the rotator

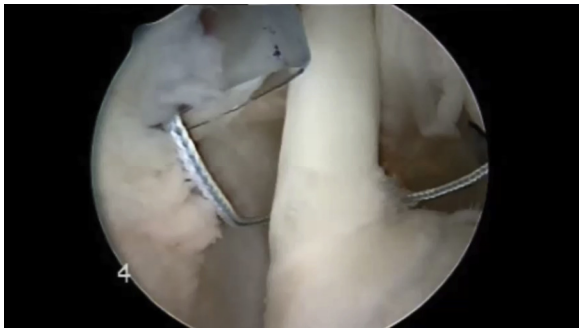

Fig 7. A permanent braided suture is introduced into the glenohumeral joint from the anterosuperior cannula while viewing from the posterior portal of a right shoulder using a 30° arthroscope with the patient in lateral decubitus position.

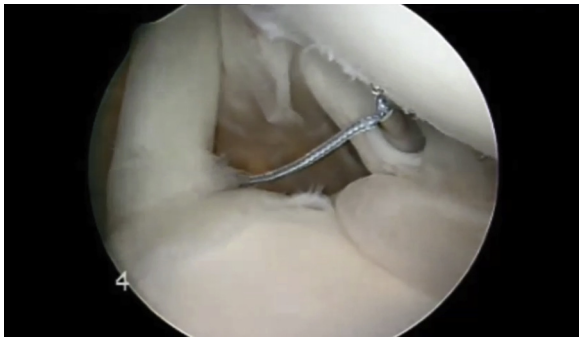

Fig 8. The permanent braided suture end is transferred to the retriever that has been previously introduced into the glenohumeral joint through the middle glenohumeral ligament while viewing from the posterior portal of a right shoulder using a 30° arthroscope with the patient in lateral decubitus position.

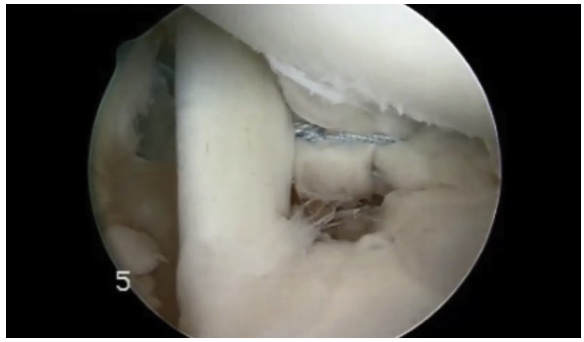

Fig 10. A sliding, locking knot with alternating half-hitches is tied, thereby placating intra-articular and extra-articular portions of the rotator interval capsule while viewing from the posterior portal of a right shoulder using a 30° arthroscope with the patient in lateral decubitus position.

interval at its superior margin and posterior to the long head of the biceps tendon. A 5-mm threaded cannula is then advanced into the glenohumeral joint immediately posterior to the biceps tendon by using the spinal needle as a guide. The previously placed anterior inferior 8-mm cannula is retracted slightly so that it is just anterior to the rotator interval capsule and extracapsular to the glenohumeral joint. A 60° penetrating suture retriever (Mitek IDEAL; DePuy Synthes, Raynham, MA) is then advanced into the joint through this anterior inferior cannula, piercing the rotator interval capsule at its inferior margin and the middle glenohumeral ligament just superior to the subscapularis tendon. An arthroscopic grasper, holding a No. 2 permanent braided suture, is then inserted through the anterosuperior cannula into the glenohumeral joint and is used to hand off the leading end of this suture to the retrograde retriever that had been previously advanced through the rotator interval capsule and MGHL (Figs 7 and 8). After the suture transfer to this retriever, it is carefully retracted until the retractor tip is extra-articular and immediately anterior to the rotator interval capsule. The retriever, now loaded with the No. 2 suture, is then redirected anteriorly and superiorly. Both the extra-articular coracohumeral ligament and the intra-articular superior glenohumeral ligament are pierced with the retriever as it reintroduced into the glenohumeral joint through the most superior margin of the rotator interval capsule (Fig 9).

Once the retriever has been reintroduced into the glenohumeral joint, the suture end is then passed back to the grasper still positioned in the anterosuperior portal and retrieved out of this cannula. At this point, both limbs of the suture are exiting the anterosuperior cannula. A sliding locking knot is then tied outside the anterosuperior portal and advanced into the joint while the arm is positioned in approximately 30° of abduction and 30° of external rotation. Increasing the amount of abduction and external rotation of the arm during knot tying may be considered when the procedure is carried

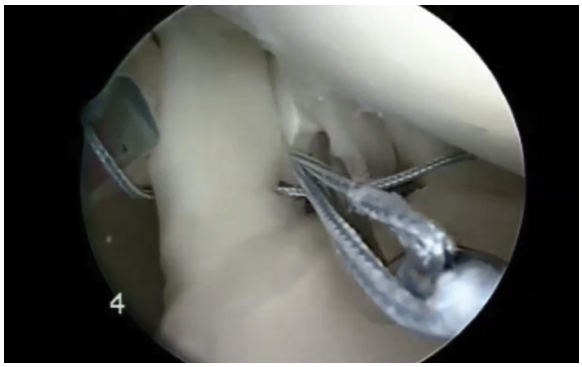

Fig 9. The suture-passing device is introduced back into the glenohumeral joint after it has been used to pierce the coracohumeral ligament and superior glenohumeral ligament while viewing from the posterior portal of a right shoulder using a 30° arthroscope with the patient in lateral decubitus position.

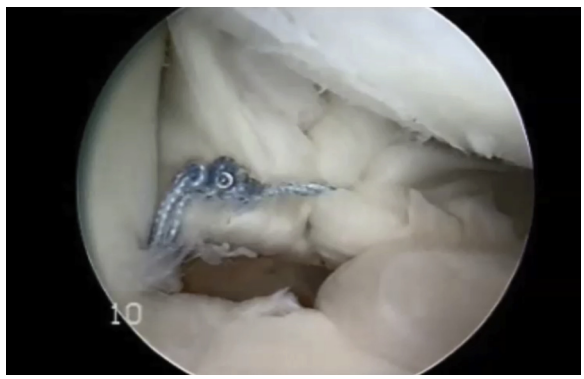

Fig 11. The completed rotator interval plication using the "seamster" technique is visualized while viewing from the posterior portal of a right shoulder using a 30° arthroscope with the patient in lateral decubitus position.

Table 1. Surgical Pearls and Pitfalls of Rotator Plication: "Seamster" Technique

Pearls
Placing the 2 anterior cannulas at the superior and inferior borders of the rotator interval capsule maximizes the amount of rotator interval capsule that can be plicated.
Using a sharp retriever makes passage of the suture through the coracohumeral ligament easier and more reliable.
In cases in which the middle glenohumeral ligament is poorly defined the suture retriever can be passed through the superior border of the subscapularis and included in the plication.
Absorbable suture material may be substituted for permanent suture in some clinical situations.
Pitfalls
Care should be taken when blindly redirecting the suture retriever to avoid iatrogenic injury of structures within or adjacent to the subacromial space.
Care should be taken when establishing the anterosuperior portal site to avoid iatrogenic injury to either the biceps tendon or the anterior margin of the supraspinatus tendon.

out on an overhead athlete in an effort to maximize postoperative external rotation. This knot is then completed by securing 3 alternating half-hitches tied arthroscopically under direct visualization (Fig 10), resulting in approximation of the SGHL and MGHL as well as incorporation of the extra-articular portions of the rotator interval capsule including the CHL. A suture cutter is then used to cut the suture ends, completing the rotator interval plication (Fig 11).

Discussion

The rotator interval is composed of both intra-articular structures such as the superior and middle glenohumeral ligaments and the extra-articular coracohumeral ligament. The coracohumeral ligament plays an important factor in limiting posterior translation of the humerus and provides additional stability when incorporated into a rotator interval plication.[10] Additionally, the position of the arm during suture tying is important. Numerous studies have shown postoperative loss of external rotation following plication.[14-17] The authors recommend positioning the arm in 30° of abduction and 30° of external rotation during knot tying to help minimize the risk of motion loss postoperatively. Also, the surgeon should remain cognizant of the biceps tendon when passing sutures around the rotator interval capsule and into the glenohumeral joint so as to avoid inadvertently incorporating the biceps into this plication of the rotator interval (Table 1).

In the absence of any complicating issues, cases of rotator interval plication are rehabilitated using a 5-phase therapy program. The initial 10 days postoperative focuses on a gradual increase in passive motion, while carefully maintaining the integrity of the repair. After this initial phase and through week 6, full range of passive motion is gained and reestablishment of dynamic shoulder stability is begun. Postoperative weeks 7 through 14 consist of full active range of motion, gradual restoration of shoulder strength, and gradual return to functional activities. Postoperative weeks 15 through 22 are used to continue strengthening. The final therapy phase, from week 23 through 36, focus on a return to strenuous work and sports activities.

Table 2. Advantages and Disadvantages of "Seamster" Technique

Advantages	Disadvantages
Allows for incorporation of both the intra-articular and extra-articular components of the rotator interval capsule, including the coracohumeral ligament.	Requires blind advancement of suture using the suture retriever.
Allows for direct visualization of knot tying (no blind tying).	Requires the use of 2 anterior portals. Care should be taken to avoid inadvertent incorporation of the biceps tendon into the plication.

Conclusions

Many techniques exist for arthroscopic rotator interval plication. The "seamster" technique, as described by the authors, is reproducible and can be reliably accomplished. The "seamster" technique has the advantage of allowing for the incorporation of both intra-articular and extra-articular ligaments into the rotator interval closure. Also, the "seamster" technique allows for knots to be tied under direct arthroscopic visualization, thus helping to ensure that they are consistently well tied and secure (Table 2). Limitations or disadvantages to this technique include establishing another anterior portal to allow optimal working access, blind advancement of the suture while using the suture retriever in the extra-articular, and the risk of inadvertently incorporating the biceps tendon into the plication (Table 2).

References

1. Stokes DA, Savoie FH, Field LD, et al. Arthroscopic repair of anterior glenohumeral instability and rotator interval lesions. *Orthop Clin N Am* 2003;34:529-538.
2. Jost B, Koch PP, Gerber C. Anatomy and functional aspects of the rotator interval. *J Shoulder Elb Surg* 2000;9:336-341.
3. Treacy SH, Field LD, Savoie FH. Rotator interval capsule closure: An arthroscopic technique. *Arthroscopy* 1997;13:103-106.
4. Blasier RB, Soslowsky LJ, Malicky DM, et al. Posterior glenohumeral subluxation: Active and passive stabilization in a biomechanical model. *J Bone Joint Surg Am* 1997;79:433-440.

5. Itoi E, Berglund LJ, Grabowski JJ, et al. Superior-inferior stability of the shoulder: Role of the coracohumeral ligament and the rotator interval capsule. *Mayo Clin Proc* 1998;73:508-515.
6. Harryman DT II, Sidles JA, Harris SL, et al. The role of the rotator interval capsule in passive motion and stability of the shoulder. *J Bone Joint Surg Am* 1992;74:53-66.
7. Savoie FH, Holt MS, Field LD, et al. Arthroscopic management of posterior instability: Evolution of technique and results. *Arthroscopy* 2008;24:389-396.
8. Gartsman GM, Roddey TS, Hammerman SM. Arthroscopic treatment of anterior-inferior glenohumeral instability: two to five year follow-up. *J Bone Joint Surg Am* 2000;82:991-1003.
9. Coughlin RP, Bullock GS, Shanmugaraj A, et al. Outcomes after arthroscopic rotator interval closure for shoulder instability: A systematic review. *Arthroscopy* 2018;34:3098-3108.
10. Gaskill TR, Taylor DC, Millett PJ. Management of multidirectional instability of the shoulder. *J Am Acad Orthop Surg* 2011;19:758-767.
11. Giuseffi S, Field LD. *Arthroscopic posterior Bankart repair.* The Shoulder: AANA Advanced Arthroscopic Surgical Techniques 2016. Ch. 21.
12. Provencher MT, Peebles LA. Editorial Commentary: Rotator interval closure of the shoulder continues to be a challenge in consensus on treatment. *Arthroscopy* 2018;34:3109-3111.
13. Hobgood ER, Field LD. Arthroscopic rotator interval plication: Rationale, indications, and technique. *Techn Shoulder Elb Surg* 2009;10:26-30.
14. Plausinis D, Bravman JT, Heywood C, Kummer FJ, Kwon YW, Jazrawi LM. Arthroscopic rotator interval closure: Effect of sutures on glenohumeral motion and anterior-posterior translation. *Am J Sports Med* 2006;34:1656-1661.
15. Provencher MT, Mologne TS, Hongo M, Zhao K, Tasto JP, An KN. Arthroscopic versus open rotator interval closure: Biomechanical evaluation of stability and motion. *Arthroscopy* 2007;23:583-592.
16. Yamamoto N, Itoi E, Tuoheti Y, et al. Effect of rotator interval closure on glenohumeral stability and motion: A cadaveric study. *J Shoulder Elb Surg* 2006;15:750-758.
17. Sodl JF, McGarry MH, Campbell ST, Tibone JE, Lee TQ. Biomechanical effects of anterior capsular plication and rotator interval closure in simulated anterior shoulder instability. *Knee Surg Sports Traumatol Arthrosc* 2016;24:365-373.